

# A Multicenter Randomized Comparative Trial of Implants with Different Abutment Interfaces to Replace Anterior Maxillary Single Teeth

Lyndon F. Cooper, DDS, PhD<sup>1</sup>/Glenn Reside, DDS<sup>2</sup>/Clark Stanford, DDS, PhD<sup>3</sup>/Chris Barwacz, DDS<sup>4</sup>/Jocelyne Feine, DDS, PhD<sup>5</sup>/Samer Abi Nader, DDS, MS<sup>6</sup>/E. Todd Scheyer, DDS, MS<sup>7</sup>/Michael McGuire, DDS<sup>7</sup>

**Purpose:** The implant-abutment interface may affect peri-implant mucosal architecture, and influence health and esthetics. The goal of this 1-year follow-up report of a 5-year clinical investigation was to examine the peri-implant mucosal tissue responses to different implant-abutment interface designs. **Materials and Methods:** Subjects requiring an anterior maxillary implant were recruited. Tooth extractions, with or without preservation or ridge augmentation procedures, were performed as required. After 5 months of healing, one of three different implant-abutment combinations (conical interface [CI] n = 48); flat-to-flat interface [FI] n = 49); or platform switch interface [PS] n = 44) was placed and provisionalized. Twelve weeks later, permanent crowns were placed and data gathered throughout the first year. Peri-implant mucosal architecture and bone levels were evaluated clinically, photographically, and radiographically. **Results:** At 1 year, seven FI and six PS implants failed and two FI and two PS implant participants were lost to follow-up, resulting in survival rates of 100% (CI), 85.7% (FI), and 86.4% (PS) (90.8% overall). Marginal bone level changes were -0.22 mm (CI, P < .05), -1.2 mm (FI, P < .05), and -1.32 mm (PS, P < .05) after 1 year. Marginal bone level stability ( $\leq 0.5$ -mm bone loss or gain) was recorded for 87% (CI), 8% (FI), and 27% (PS) of implants. Measurement of midbuccal mucosal zenith and papilla positions revealed no change in the mucosal positions and 0.2 to 0.3 mm of gain in papilla dimensions in all groups. **Conclusion:** Significant differences in marginal bone loss were observed among the three implant-abutment interfaces. At 1 year follow-up, changes in the buccal mucosal zenith position or papilla dimensions were not discernable. A continued longitudinal evaluation of peri-implant bone and mucosal changes around these different interfaces is ongoing. INT J ORAL MAXILLOFAC IMPLANTS 2015;30:622–632. doi: 10.11607/jomi.3772

**Key words:** immediate provisionalization, esthetics, marginal bone levels, peri-implant mucosa

Choosing implant therapy and the mode of intervention (immediate vs delayed placement, immediate vs conventional loading) requires a comprehensive

evidence-based approach. Dental implant success is multifactorial. Based on a meta-analysis of five studies with 248 implants, Atieh et al<sup>1</sup> found that compared with conventional loading, immediate loading of single implant crowns was associated with a significantly higher risk of implant failure (5.07, 95% confidence interval [CI] = 2.00–12.84). Immediate nonocclusal loading (provisionalization) was also associated with higher risk (4.76; 95% CI = 1.74–13.02). Despite the controversies, immediate loading offers the following advantages: (1) patients prefer the fewer interventions required with immediate loading protocols<sup>2</sup> and (2) many authors suggest that immediate provisionalization improves esthetics, particularly regarding per-implant soft tissue responses.

These procedures may have associated risks. Chen and Buser<sup>3</sup> concluded that clinical and esthetic complications of single tooth implantation included recession of the buccal mucosal margin, which was associated with a history of a thin tissue biotype, buccal malposition of the implant, and a thin or damaged buccal bone wall. More recently, Cosyn et al<sup>4</sup> concluded that

<sup>1</sup>Stallings Distinguished Professor, Department of Prosthodontics, University of North Carolina, Chapel Hill, North Carolina, USA.

<sup>2</sup>Department of Oral Maxillofacial Surgery, University of North Carolina, Chapel Hill, North Carolina, USA.

<sup>3</sup>Centennial Fund Professor, Department of Prosthodontics, University of Iowa, Iowa City, Iowa, USA.

<sup>4</sup>Craniofacial Clinical Research Center, University of Iowa, Iowa City, Iowa, USA.

<sup>5</sup>Oral Health and Society Research Unit, Faculty of Dentistry, McGill University, Montreal, Canada.

<sup>6</sup>Director, Division of Restorative Dentistry, McGill University, Montreal, Canada.

<sup>7</sup>PerioHealth Professionals, Houston, Texas, USA.

**Correspondence to:** Dr Lyndon F. Cooper, 330 Brauer Hall, CB#7450, University of North Carolina School of Dentistry, Chapel Hill, NC 27599. Fax: 919-537-3977. Email: lyndon\_cooper@dentistry.unc.edu

©2015 by Quintessence Publishing Co Inc.

**Table 1 Study Outcome Measures**

Variable	Outcome
<b>Primary outcome variable</b>	
Soft tissue response	Soft tissue change from baseline to 1 year (for the buccal gingival zeniths)
<b>Secondary outcome variables</b>	
Soft tissue response	Soft tissue changes up to 5 years (for the buccal gingival zeniths) Soft tissue changes (for the mesial and distal papilla, separately) Cytokines in peri-implant sulcular fluid Plaque, bleeding on probing, and probing pocket depth Pink esthetic score
Soft/bone tissue response	Alveolar ridge architecture alterations
Bone tissue response	Marginal bone level alterations (mesial and distal)
Implant success/survival	
Safety	Adverse events/adverse device effects and serious adverse events
Patient reported outcomes	Patient questionnaire with esthetic focus

the risk of advanced soft tissue recession may be reduced when specific local features (intact buccal bone wall and thick gingival biotype) and specific protocols (flapless surgery and immediate implant crowns) are provided. Den Hartog et al<sup>5</sup> concluded that data regarding soft-tissue aspects were underrepresented in existing systematic reviews. Levi et al<sup>6</sup> reported that both definitive restoration shape and appearance were strongly associated with patient satisfaction. The importance of peri-implant tissues on esthetics is illustrated by findings that both dental professionals and clinicians rated the peri-implant mucosa less satisfactory than the implant-supported crown.<sup>7</sup>

Emerging objective measures of dental implant esthetics include soft tissue parameters. Jemt<sup>8</sup> first addressed the importance of interproximal peri-implant mucosal form with the papilla index. Meijer et al<sup>9</sup> introduced the “implant crown esthetic index” (including nine parameters defining dimensions and form of the crown as well as the labial peri-implant mucosa). Alternatively, the pink esthetic score (PES) was introduced with a focus solely on peri-implant mucosal features divided into seven parameters (mesial and distal papilla, soft tissue level, soft tissue contour, soft tissue color, soft tissue texture, and alveolar process deficiency).<sup>10</sup> Belser et al<sup>11</sup> modified the PES and proposed an implant restoration index (white esthetic score [WES]) for analyzing single tooth implants. Continuing this trend, more investigators studied factors that influence dental implant esthetics. For example, Kan et al<sup>12</sup> demonstrated that tissue dimensions and implant/tissue relationships influenced outcomes. The surgical approach influences outcomes.<sup>13</sup> Macro design of the abutment was also shown to positively influence the recorded PES.<sup>14</sup> Material selection influenced esthetic outcomes by influencing tissue color.<sup>15</sup> Although the impact of many features of the implant/abutment/

tissue complex have been considered experimentally, few investigations have directly investigated the influence of the implant-abutment interface design on dental implant esthetics.

The implant-abutment interface varies remarkably among many different implants. The relative biologic impact of different implant-abutment connection designs, however, is undefined. Finite element models repeatedly demonstrate that design should influence the integrity of the interface and potential related tissue responses.<sup>16–17</sup> Few clinical studies have investigated the influence of implant-abutment interface design on dental implant outcomes, including dental esthetic parameters. The primary objective of this 5-year prospective evaluation was to compare the buccal soft tissue changes occurring around single tooth replacements in the maxilla using three different implant-abutment interface designs. A related, secondary objective (Table 1) was the comparison of marginal bone responses; both the primary and secondary objectives are the focus of this initial 1-year follow-up report.

## MATERIALS AND METHODS

### Overview

Adults in need of one or more single tooth replacements in the anterior maxilla including in the first premolar region were recruited as approved by the institutional review board (IRB). Individuals meeting specific inclusion and exclusion criteria (Table 2) were enrolled in one of the four study centers. To control variables related to extraction sites, extraction sockets and deficient healed alveolar ridges were augmented using human recombinant bone morphogenetic protein 2 (rhBMP2, Infuse, Medtronic). After 5 months of healing, participants were randomized to receive one

**Table 2 Inclusion and Exclusion Criteria**

Inclusion criteria	Exclusion criteria
<ol style="list-style-type: none"> <li>1. Provision of informed consent</li> <li>2. Age <math>\geq</math> 18 years</li> <li>3. In need of one or more single implants replacing missing or nonrestorable teeth in the maxilla within region 14 to 24</li> </ol> <p><b>The following should be considered at inclusion but cannot be fulfilled until visit 2</b></p> <ol style="list-style-type: none"> <li>4. Edentulous for at least 5 months at study site</li> <li>5. A buccal-lingual bone width at study site of at least 5.5 mm</li> <li>6. A mesial-distal bone level distance between adjacent teeth at study site of at least 5.5 mm</li> <li>7. A keratinized midbuccal mucosal height of at least 2 mm at study site</li> <li>8. Teeth adjacent (mesial and distal) to study site must consist of two stable teeth on natural roots without signs of periodontal bone loss (<math>&gt;1</math> mm) and/or significant soft tissue loss</li> <li>9. Teeth adjacent (mesial and distal) to study site must demonstrate a stable occlusal guidance that will allow nonfunctional disclusion in all eccentric positions</li> <li>10. An opposing dentition with teeth, implants, or prosthesis</li> </ol>	<ol style="list-style-type: none"> <li>1. Insufficient interocclusal distance for implant placement and restoration at study site</li> <li>2. Tooth adjacent (mesial and/or distal) is ankylosed</li> <li>3. More than 2 mm vertical bone loss as measured from the midbuccal crest of bone on the adjacent teeth</li> <li>4. Site development (bone tissue) performed at less than 5 months before visit 2</li> <li>5. Untreated rampant caries and/or uncontrolled periodontal disease</li> <li>6. Class II division 2 malocclusion (Edward Hartley angle)</li> <li>7. Use of tobacco within last 6 months</li> <li>8. Uncontrolled diabetes</li> <li>9. Current alcohol or drug abuse</li> <li>10. Systemic or local disease or condition that compromises postoperative healing and/or osseointegration</li> <li>11. Use of any substance that will influence bone metabolism</li> <li>12. Need for systemic corticosteroids or any other medication that would influence postoperative healing and/or osseointegration</li> <li>13. History of radiation in the head and neck region</li> <li>14. Known pregnancy; pregnancy tests will be performed as per local requirements</li> <li>15. Unable or unwilling to return for follow-up visits for 5 years</li> <li>16. Unlikely to comply with study procedures according to investigators' judgment</li> <li>17. Involvement in the planning and conduct of the study (applies to both sponsor staff or staff at the study center)</li> <li>18. Previous enrollment or randomization of treatment in the present study</li> </ol>

of three different implants (conical interface [CI], OsseoSpeed, Dentsply Implants; flat-to-flat interface [FI], NobelSpeedy Replace, Nobel Biocare; or platform switch interface [PS], NanoTite Certain Prevail, Biomet 3i). Implants were placed using a standardized immediate provisionalization protocol controlling and recording depth of implant placement and using titanium abutments and acrylic crowns. After 8 weeks, a final impression was made and definitive zirconia abutments (Atlantis abutments, Dentsply Implants) with lithium disilicate crowns (E-max, Ivoclar) were delivered 4 weeks later. Clinical, photographic, and radiographic evaluations were performed throughout the first year. All procedures were in accordance with the ethical standards of the IRB and the last update of the Helsinki Declaration.

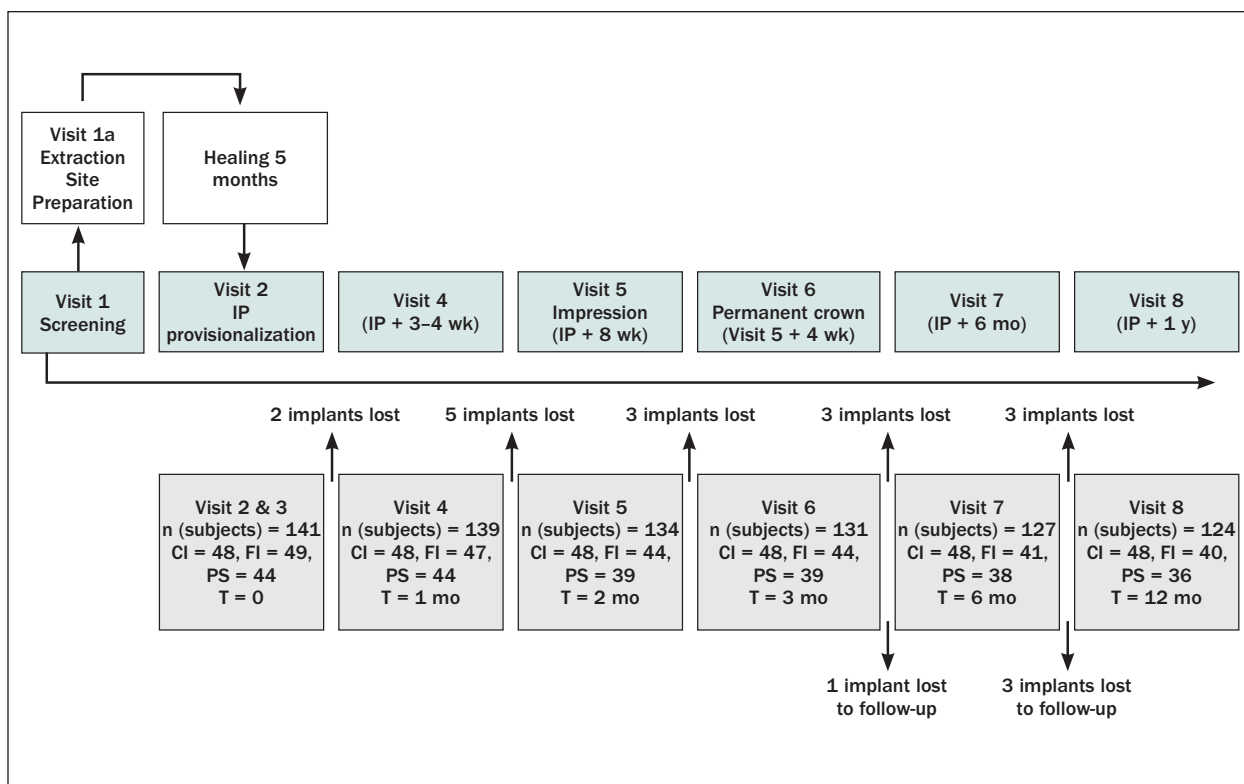
### Surgical Procedures

**Site Development Procedures.** After collecting IRB-approved informed consent, preoperative study casts were made and treatment plans were established. Ridge preservation and/or augmentation procedures were performed using rhBMP-2 according to manufacturer's recommendation with or without the inclusion

of space-maintaining materials (mineralized bone allograft) as indicated by the clinical situation. These sites were evaluated clinically for implant placement after 5 months of healing.

### Implant Placement and Provisionalization

At the moment of implant placement, the implant type was revealed from the randomization envelope. The three different implants were placed using a flapless approach and drilling protocols recommended by the individual implant manufacturers. Each implant was placed such that the implant-abutment interface was clinically positioned 3 mm apical to the planned gingival (peri-implant mucosal) zenith. The depth of implant placement was recorded. Primary stability was indicated by the absence of lateral or axial implant movement (according to the manufacturer's suggested torque requirements). At this time, if further bone and soft tissue grafting was performed, it was recorded and considered a protocol deviation. Immediate provisionalization was performed using a titanium abutment (CI = Direct Abutment, Dentsply Implants; FI = Snappy Abutments, Nobel Biocare; PS = GingiHue Abutment, Biomet 3i). A bis-acryl resin temporary crown was



**Fig 1** Study flow chart. The first year of this study involved eight main visits. Site development involved a 5-month healing period. The baseline for marginal bone measures was implant placement and loading, and includes 12 months of follow-up (visit 2 to visit 8). Because of the change in the provisional crown, two soft tissue baselines were defined. One is at visit 4 for the provisional crown, and the other is at visit 6 for the permanent crown. The progression of implant follow-up is indicated according to time and visit number. The implants lost and implants lost to follow-up are indicated. IP = implant placement.

fabricated from a putty matrix, relined, and refined to fit the prefabricated abutment margins. Provisional crowns were screw retained or cemented with provisional cement and placed without occlusal contacts in centric or eccentric positions. Implants lacking sufficient primary stability were not restored at this time, but provisionalized later at the discretion of the clinician.

Postoperative instructions included the prescription of antibiotics (amoxicillin 500 mg three times per day or clindamycin 600 mg four times per day for 7 days), chlorhexidine mouthwash, and analgesic as needed for pain. Participants were clinically evaluated after provisionalization at 1 week and at the 3- to 4-week time points. Excess cement was removed or implant crown contacts were adjusted as required.

### Definitive Restoration

Eight weeks after implant site healing, provisional restorations were removed and the stability of the implant was verified by connection of the implant-level impression coping to the implant without mobility or pain. An elastomeric final impression of the implant was made, the interocclusal registration and mandibular impression were made, shade selection was performed, and

the materials were sent to one central dental laboratory (Studio 32, Cedar Rapids, Iowa) for fabrication of a final zirconia abutment using computer-aided design/computer-assisted manufacture (Atlantis abutments, Dentsply Implants), a related abutment screw, and a final lithium disilicate crown (IPS e-max, Ivoclar Vivadent). Four weeks later, the definitive restorations were cemented using RelyX Unicem (3M Espe).

### Evaluations

From inclusion to the 1-year follow-up, at least eight visits were scheduled for each participant (Fig 1). The measured variables and the frequency of evaluation are represented in Table 3. This report focuses on marginal bone level changes and peri-implant mucosal changes occurring at interproximal and midbuccal locations.

### Implant Survival

Each implant was categorized as surviving (in situ), failed (removed), or unaccounted for (lost to follow-up). A life table analysis was performed (Kaplan Meyer). Implant failures and other complications were recorded as adverse device effects.

**Table 3 Summary of Study Variables and Frequency of Evaluation\***

Variable	Visit 2 IP	Visit 4 IP + 3–4 wk	Visit 6 IP + 12 wk	Visit 7 IP + 6 mo	Visit 8 IP + 12 mo
Crown	Prov	Prov	Prov	Perm	Perm
Patient questionnaire <sup>†</sup>		X	X	X	X
PISF <sup>†</sup>		X	X		X
Gingival zenith and papilla: Canfield and clinical		X	X	X	X
PES <sup>†</sup>		X	X	X	X
PPD and BoP		X (BoP only)	X	X	X
Radiograph	X			X	X
Adverse device effects (complications)	X	X	X	X	X

\*Impressions were also taken before visit 2 and at visits 2, 5, 6, 7, and 8 to evaluate changes in the alveolar ridge dimension by scanning study casts.

<sup>†</sup>Topics of separate articles.

IP = implant placement; Prov = provisional crown; Perm = permanent crown; PISF = peri-implant sulcular fluid; PES = pink esthetic score;

PPD = probing pocket depth; BoP = bleeding on probing.

### Marginal Bone Levels

A radiologist measured the distance from the designated implant reference points (unique for each implant system to permit unambiguous identification in radiographs) to the most coronal bone-to-implant contact on the mesial and distal aspects of the implants. The mean of these two measures was calculated. Changes in these distances from baseline (implant placement) to subsequent time points were calculated and statistically analyzed.

### Measurements of Both the Midbuccal Mucosal Zenith and the Interproximal Papilla

Both were measured directly using a UNC15 probe (Hu-Friedy) to the nearest half millimeter.<sup>18</sup> Serial standardized photographs were used to confirm these measures. A Canfield apparatus (Canfield Scientific Inc) was used to geometrically reproduce images over time. All centers used the same camera model and standard exposure settings. Each image was taken with and without a periodontal probe as an internal linear calibration. Linear measures of papilla mucosal zenith scores were made using unaltered .jpg images in Image J software. Changes in these distances from baseline (provisional or permanent crown delivery) to appropriate subsequent time points were calculated and statistically analyzed. The associated PES<sup>10</sup> was evaluated using a digital image scoring format and is the subject of a separate article.

### Statistical Analyses

Within-group and between-group comparisons were calculated using nonparametric statistics (Wilcoxon signed-rank test and Mann-Whitney *U* test, respectively) using PASW Statistics for Windows, version 18.0 (SPSS). A two-sided *P* < .05 was considered statistically significant.

## RESULTS

### Recruitment and Randomization

Among the four centers, 171 participants were recruited (visit 1, Fig 1). Of these, 30 individuals were not randomized and were excluded before implant placement (visit 2). The main reasons for exclusion included the condition of the adjacent tooth and lack of bone height or width after grafting. One hundred fifty-six implants (CI = 53, FI = 53, PS = 50) were placed in 141 participants. Per protocol, only one implant per participant was randomized for evaluation (CI = 48, FI = 49, PS = 44).

### Demographics

The mean age ± standard deviation (SD) of the 141 participants was 45 ± 16 years (range, 18–81 years). There were no age differences among the three treatment groups. Sixty-one subjects (43%) were men and 80 (57%) were women; fewer men than women were allocated to the FI group. The mean calculated body mass index (BMI) was 27 ± 6 (range, 17–54), with all three treatment groups having similar mean values. Ex-smokers comprised 28% of the population, with no differences seen among the groups (Table 4).

### Preoperative Oral Health Status

Three participants presented with abnormal jaw relations, and only three participants had periodontitis (all in the FI group). All three groups had partially edentate participants, with a mean of 22.7 (CI), 24.0 (FI), and 22.8 teeth (PS). Thirty-two individuals reported bruxism. More than 75% of participants reported that their tooth loss was caused by caries or trauma, with most other reported reasons attributed to agenesis (19%) (Table 4).

**Table 4 Study Population Demographics**

Variable	CI	FI	PS	All
No. (%)	48 (34)	49 (35)	44 (31)	141 (100)
Mean ± SD age (range) (y)	43 ± 15 (18–70)	46 ± 17 (19–78)	46 ± 16 (18–81)	45 ± 16 (18–81)
Mean ± SD BMI (range)	28 ± 7 (19–54)	27 ± 6 (18–40)	26 ± 5 (17–44)	27 ± 6 (17–54)
Sex, No. (%)				
M	25 (52)	14 (29)	22 (50)	61 (43)
F	23 (48)	35 (71)	22 (50)	80 (57)
Smoking status, No. (%)				
Nonsmoker	33 (69)	35 (71)	33 (75)	101 (72)
Ex-smoker	15 (31)	14 (29)	11 (24)	40 (28)
Oral condition				
Abnormal jaw relations, No. (%)				
With	1 (2)	0	2 (5)	3 (2)
Without	47 (98)	49 (100)	42 (95)	138 (98)
Periodontitis, No. (%)				
With	0	3 (6)	0	3 (2)
Without	48 (100)	46 (94)	44 (100)	138 (98)
Bruxism, No. (%)				
With	15 (31)	10 (20)	7 (16)	32 (23)
Without	33 (69)	39 (80)	37 (84)	109 (77)

CI = conical interface; FI = flat-to-flat interface; PS = platform switch interface; BMI = body mass index.

**Table 5 Implant Site Preparation Variables**

Variable	CI = 48		FI = 49		PS = 44		All	
	Ex	HR	Ex	HR	Ex	HR	Ex	HR
No.	24	24	24	25	20	24	68	73
Site preparation (yes/no)	24/0	14/10	23/1	12/13	19/1*	16/8	66/1 + 1*	42/31
Bone graft (yes/no)	24/0	14/0	23/0	11/1†	19/0	13/3†	66/0	38/4†
rhBMP-2 only	9	0	10	0	7	0	26	0
rhBMP-2 + other material	12	13	11	10	9	13	32	36
Other material only	3	1	2	1	3	0	8	2
Membrane (yes/no)	7/17	5/9	6/18	3/9	5/14	2/14	18/49	10/32
Aut soft tissue graft (yes/no)	2/22	0/14	1/23	1/11	1/18	3/13	4/63	4/38
Suture (yes/no)	22/2	14/0	22/2	12/0	19/0	16/0	63/4	42/0

\*Retained primary tooth extracted at time of implant placement.

†Only autogenous soft tissue graft.

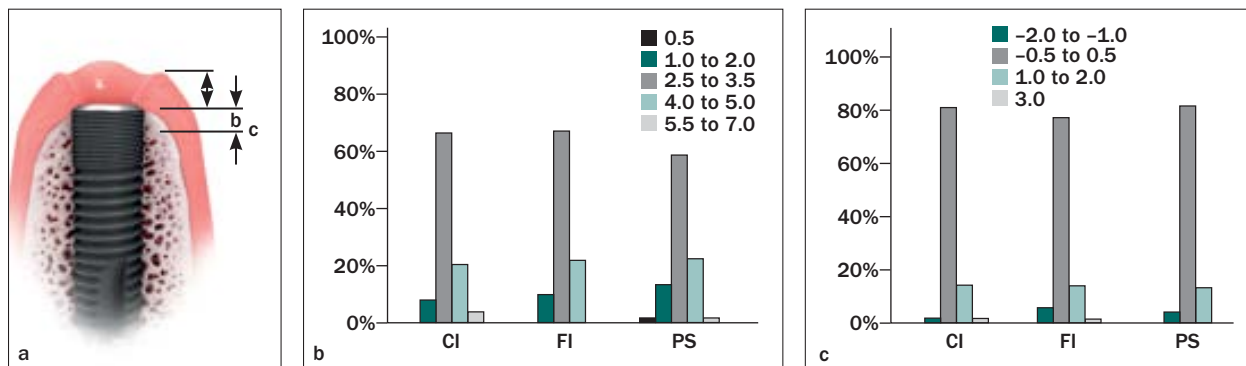
CI = conical interface; FI = flat-to-flat interface; PS = platform switch interface; Ex = extraction of tooth required; HR = healed ridge; rhBMP-2 = human recombinant bone morphogenetic protein 2; Aut = autogenous.

### Implant Site Preparation

Study participants had 68 extraction sites and 73 healed ridges. All but two of 68 extraction sites were subjected to site preservation. Forty-two of 73 healed ridges were developed using augmentation procedures (Table 5). Of the participants with 104 bone augmentation procedures, 26 were treated with rhBMP-2 adsorbed to the absorbable collagen sponge. Sixty-eight participants were treated using rhBMP-2 adsorbed to the collagen sponge with a mineralized bone allograft. Ten others were treated with the bone filler only. A membrane or autogenous soft tissue graft was used in 28 (26%) and 8 (7%) participants, respectively.

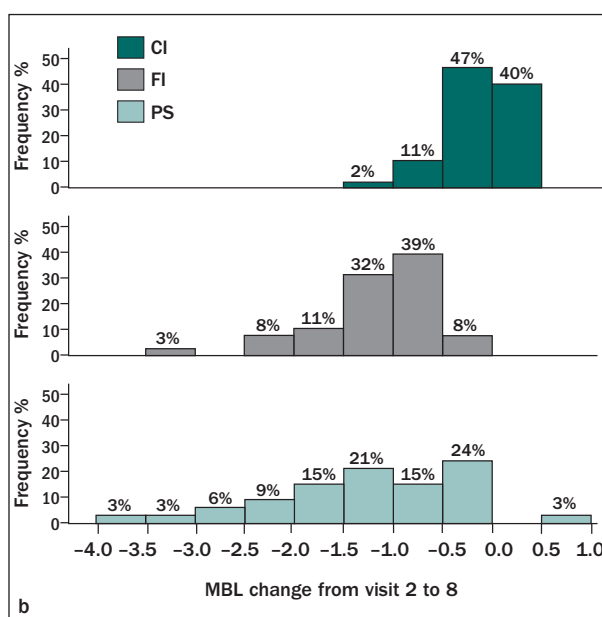
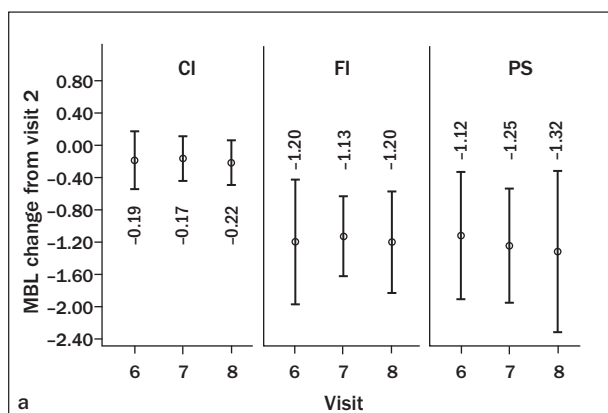
### Implant Placement, Survival, and Participant Attrition

At visit 2, 141 participants were enrolled and randomized; 48 received CI implants, 49 received FI implants, and 44 received PS implants. With the exception of one retained primary tooth with marked root resorption, the implants were placed in healed ridges, augmented ridges, preserved sockets, or healed sockets. At the time of implant placement, 19%, 16%, and 14% of CI, FI, and PS implants, respectively, required additional bone grafting. Soft tissue augmentation at the time of CI, FI, and PS implant placement was deemed esthetically necessary for 17%, 22%, and 25% of sites, respectively.



**Fig 2** (a) Location of implants measured from surgical reference points after insertion. Orientation of implant-abutment interface is measured from the buccal mucosal zenith (distance b) or measured in a vertical orientation from the bone crest (distance c). Distribution of implants (CI, FI, PS) is shown as a function of the distance (b) from the buccal mucosal zenith to the reference point (0.5 to 7.0 mm) and (c) from the buccal bone crest to the reference point (-2.0 to -1.0 mm = supracrestal placement; -0.5 to 0.5 mm = flush; 1.0 to 2.0 mm = subcrestal placement; 3.0 mm = subcrestal).

**Fig 3** (a) The average change in marginal bone level (MBL) from visit 6 to visit 8 is plotted for each group ( $\pm$  SEM). (b) The distribution of MBL changes over 1 year are revealed according to the extent of bone loss (negative) or bone gain (positive). No change ('0') is designated by the dashed line.

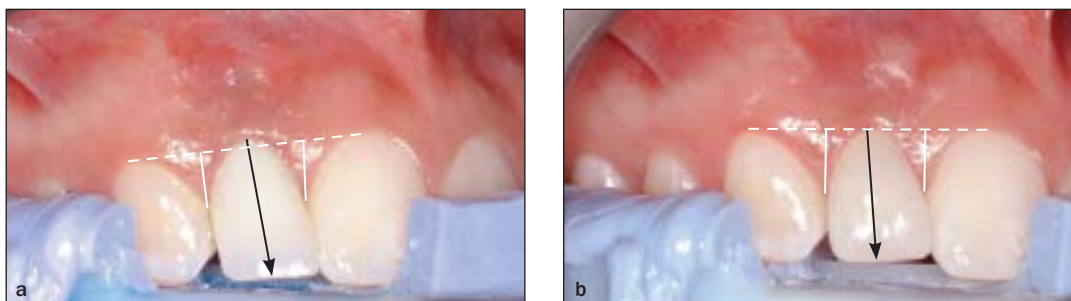


The bone quality was reported to be type 2 or 3 in more than 90% of all cases and quantity type A or B in more than 88% of all cases. The clinical decision to provisionalize the implants at placement was made in 79% (CI), 82% (FI), and 80% (PS) of cases, despite the clinician recording primary stability in 94%, 98%, and 91% of all CI, FI, and PS surgeries, respectively. Provisionalization was delayed because of bone grafting, soft tissue grafting, or other intraoperative complications such as lack of primary stability.

During the first follow-up interval (3–4 weeks), two implants (FI) were lost and before the time of implant impression (8 weeks), five additional implants failed (three FI and two PS implants). Three more PS implants were determined to have failed before the time of final crown placement. Thus, 10 implants failed early (five FI and five PS implants). During the remaining

part of the first year, three additional implants failed before 26 weeks (two FI and one PS implant; Fig 1). Four participants were lost to follow-up during the first year of follow-up. Thirteen of 141 participants experienced implant failure. The cumulative survival rate was 90.8%. At 1 year, 124 participants with 48 CI, 40 FI, and 36 PS implants were evaluated. The cumulative survival rate for each group was 100% (CI), 85.7% (FI), and 86.4% (PS).

The protocol prescribed that the implant reference point at implant placement would be placed 3 mm apical to the desired peri-implant mucosal zenith, and with the preceding bone grafting procedures, the implant-abutment interface would approximate the bone crest in its vertical orientation. Figure 2 illustrates that this therapeutic goal was achieved approximately 75% of the time for the three different implant systems.



**Fig 4** Sequential Canfield photographs of lateral incisor implant site. The impression material (purple) is attached to the Canfield apparatus bite fork and consistently positions the participant in the x, y, and z axes. White vertical lines indicate the papilla measurements made from the horizontal dashed line drawn tangent to the peri-implant mucosal zenith of adjacent teeth. Black arrows represent linear measurement made from buccal peri-implant mucosal zenith to incisal edge. Values in Table 6 are derived from these measures. Additional sequential images contain the periodontal probe to consistently calibrate dimensions among all photographs (not shown). Note that each photograph includes the gingival zenith of replaced tooth, mesial and distal papillae of replaced tooth, incisal edges of replaced tooth, and incisal edges of adjacent teeth. (a) Canfield photo of lateral incisor at 12 weeks (provisional crown), (b) at 1-year follow-up (permanent crown).

**Table 6** Changes in Peri-implant Mucosal Zenith Dimension at Implant Crown (Canfield and Clinical Measurements)\*

Time	CI		FI		PS	
	Clinical measurement (mm)	Canfield measurement (mm)	Clinical measurement (mm)	Canfield measurement (mm)	Clinical measurement (mm)	Canfield measurement (mm)
Visit 4 prov – visit 6 prov	0.0 ± 1.0 (-5.0 to 2.0)	-0.1 ± 0.5** (-1.6 to 0.8)	-0.1 ± 0.7 (-2.5 to 1.0)	0.0 ± 0.3** (-0.8 to 0.7)	0.1 ± 0.8 (-2.5 to 1.5)	0.1 ± 0.8** (-3.9 to 1.1)
Visit 6 PR – visit 7 PR	-0.1 ± 0.6 (-1.0 to 1.5)	0.0 ± 0.4 (-1.2 to 0.9)	-0.1 ± 0.7 (-1.5 to 1.0)	-0.1 ± 0.3 (-0.8 to 0.8)	0.0 ± 0.6 (-1.0 to 2.0)	0.0 ± 0.3 (-0.8 to 0.6)
Visit 6 PR – visit 8 PR	0.1 ± 0.7 (-1.5 to 2.5)	0.0 ± 0.5 (-2.0 to 1.1)	-0.1 ± 0.7*** (-2.5 to 1.5)	-0.2 ± 1.0 (-5.6 to 1.0)†	0.3 ± 0.8*** (-1.5 to 2.5)	0.0 ± 0.4 (-1.3 to 1.0)

\*Negative values indicate loss and positive, gain. Calculated mean change of Canfield measurements among all implants for visit 6 to visit 8 =  $-0.1 \pm 0.7$  mm. Calculated mean change of clinical measurements among all implants for visit 6 to visit 8 =  $0.1 \pm 0.8$  mm.

\*\* $P < .05$  for CI vs PS and FI vs PS.

\*\*\* $P < .05$  for FI vs PS.

†One implant site presented a loss of 5.6 mm. If this site is excluded, the change is  $0.0 \pm 0.5$  mm. CI = conical interface; FI = flat-to-flat interface; PS = platform switch interface; Prov = provisional restoration; PR = permanent restoration.

### Marginal Bone Level

Marginal bone level changes were  $-0.22$  mm (CI,  $P < .05$ ),  $-1.2$  mm (FI,  $P < .05$ ), and  $-1.32$  mm (PS,  $P < .05$ ) after 1 year. The marginal bone level changes from implant placement to 1-year follow-up revealed significant differences between CI implants and both FI and PS implants ( $P < .05$ ). The measured changes at 1 year were  $-0.22 \pm 0.28$  mm (range,  $-1.1$  to  $0.2$  mm) in CI implants, whereas changes in FI and PS implants revealed similar bone loss ( $-1.20 \pm 0.64$  mm [range,  $-3.4$  to  $-0.1$  mm] and  $-1.32 \pm 1.01$  mm [range,  $-3.7$  to  $0.9$  mm], respectively) (Fig 3a). Marginal bone level stability ( $\leq 0.5$  mm bone loss after 12 months) was recorded for 87% (CI), 8% (FI), and 27% (PS) of implants (Fig 3b).

### Peri-implant Soft Tissues

On clinical evaluation, inflammation measured as bleeding on probing was generally absent ( $< 20\%$ ) with all three implant systems. When measurements from the

Canfield photographic images were compared for the mucosal zenith dimension and the visualized papilla, there were no statistically significant differences in the changes in the buccal peri-implant mucosal zenith levels (mean,  $0.1 \pm 0.7$ ) from the permanent crown placement to 12 months after implant placement (Fig 4). The mean  $\pm$  SD changes of buccal peri-implant mucosal zenith height made from the time of delivery of the permanent crown (visit 6) to 1 year after implant placement (visit 8) was  $0.0 \pm 0.5$  mm in the CI group (range,  $-2.0$  to  $1.1$  mm),  $-0.2 \pm 1.0$  mm in the FI group (range,  $-5.6$  to  $1.0$  mm), and  $0.0 \pm 0.4$  mm in the PS group (range,  $-1.3$  to  $1.0$  mm). Similar results were observed through direct clinical measurements (Table 6). Overall, the papilla heights trended toward an increase from permanent crown placement to 12 months after implant placement (mesial papilla =  $0.3 \pm 0.5$  mm, distal papilla =  $0.2 \pm 0.5$  mm), with no statistically significant difference between treatment groups (Table 7).



**Table 7 Changes in Papilla Dimensions at Implant Crowns (Canfield Measurements)\***

Time	CI		FI		PS	
	Mean $\pm$ SD change (range)	Mesial papilla (mm)	Distal papilla (mm)	Mesial papilla (mm)	Distal papilla (mm)	Mesial papilla (mm)
Visit 4 – visit 6 prov	0.2 $\pm$ 0.7 (-1.2 to 2.8)	0.3 $\pm$ 0.4 (-0.4 to 2.2)	0.2 $\pm$ 0.6 (-0.9 to 2.2)	0.1 $\pm$ 0.5 (-1.5 to 1.7)	0.1 $\pm$ 0.6 (-1.5 to 1.3)	0.2 $\pm$ 0.5 (-1.5 to 2.2)
Visit 6 PR – visit 7 PR	0.2 $\pm$ 0.5 (-0.9 to 1.7)	0.2 $\pm$ 0.4 (-0.7 to 1.8)	0.1 $\pm$ 0.6 (-0.6 to 1.8)	0.1 $\pm$ 0.4 (-0.8 to 0.9)	0.2 $\pm$ 0.4 (-1.0 to 1.3)	0.1 $\pm$ 0.4 (-0.8 to 1.8)
Visit 6 PR – visit 8 PR	0.2 $\pm$ 0.5 (-1.1 to 1.4)	0.2 $\pm$ 0.3 (-0.3 to 1.1)	0.4 $\pm$ 0.5 (-0.6 to 2.1)	0.2 $\pm$ 0.6 (-0.9 to 2.0)	0.2 $\pm$ 0.6 (-0.9 to 1.7)	0.2 $\pm$ 0.5 (-0.9 to 2.0)

\*Negative values indicate loss and positive, gain. Calculated mean change among all implants for visit 6 to visit 8 = 0.3  $\pm$  0.5 (mesial) and 0.2  $\pm$  0.5 (distal).

CI = conical interface; FI = flat-to-flat interface; PS = platform switch interface; Prov = provisional; PR = permanent restoration.

## DISCUSSION

This prospective clinical investigation sought as a primary outcome to measure the peri-implant tissue responses after the immediate provisionalization of single crowns placed on implant-abutment connections representing CI, FI, or PS implants. At the 12-month time point, significant differences in marginal bone level changes, but not soft tissue parameters, were revealed among the groups. Although not the primary objective of this investigation, the implant survival rates differed among the three designs.

Immediate provisionalization of single tooth implants replacing anterior maxillary teeth offers specific advantages that include the rapid clinical progression of therapy that is appreciated by patients.<sup>2</sup> Forgoing the inconvenience of partial edentulism is a second advantage of practical merit. Recent systematic reviews conclude that immediate provisionalization results in little reduction in implant survival compared with conventional single tooth implant therapy.<sup>19</sup> The implant systems investigated herein have been studied in prior prospective evaluations of immediate provisionalization protocols. For the CI system, implant survival after early or immediate loading was reported to be 92.6% to 98%.<sup>20–22</sup> Recent studies of the FI system also revealed success after early/immediate loading, with survival rates higher than 95%.<sup>23,24</sup>

The presently recorded lower survival of immediately provisionalized implants was unexpected. The PS implant was reported to provide 94.9% to 99.4% cumulative survival rates in separate studies of immediate provisionalization.<sup>25–28</sup> The present disparity with previously reported outcomes is acknowledged; however, a larger study specifically designed to distinguish the survival of implants of different designs would be needed to appropriately confirm this or previous alternative results.

Implant designs are proposed to influence marginal bone levels. This study demonstrates that different initial bone responses were measured in implants with different implant-abutment interface designs and confirms previous comparison of different interface designs.<sup>29</sup> The magnitude of marginal bone level changes reported in the present study is wholly consistent with previous reports from cohort studies. Fischer et al<sup>23</sup> reported a mean bone loss of 1.5  $\pm$  1.0 mm during 1 year for single tooth FI implants, and Meloni et al<sup>30</sup> reported a mean marginal bone loss of 1.35  $\pm$  0.25 mm 2 years after immediate placement and loading. Arnhart et al<sup>31</sup> stated that FI implants demonstrated 0.85-mm bone loss following immediate loading after placement in healed implant sites. Platform switching is suggested to prevent or reduce crestal bone loss. Investigations comparing the marginal bone levels of PS implants with other implant-abutment interface designs have yielded mixed results.<sup>32–34</sup> Telleman et al<sup>35</sup> reported that the mean marginal bone loss for PS implants in posterior tooth replacement was 0.48  $\pm$  0.46 mm. Mura<sup>28</sup> found a mean marginal bone level of 2.45  $\pm$  1.29 mm in PS implants. More recently, a 3-year investigation found no difference in marginal bone level changes approximating 0.7 mm (measured with panoramic radiography) in PS implants compared with standard platform implants.<sup>36</sup> One possible limitation of this comparative study is that the expanded dimension of the implant neck (which enables horizontal displacement of the interface) reduced the crestal bone and connective tissue volume surrounding the implant-abutment interface. This concept is supported by the finding that when single 4- and 5-mm implants were compared, a tendency of greater bone loss was present in wider implants.<sup>35</sup> Other possible confounding factors may influence the response at implant platforms, including the apico-coronal position of the implants in relation to crestal bone, the various implant microtexture, the degree of platform switch, and the examination method.<sup>37</sup>

A change of  $-0.22$  mm in CI implant measurements is consistent with those found in previous investigations from the present and other laboratories.<sup>17,20,38</sup> A recent systematic review concluded that studies of this particular implant system report marginal bone level changes of  $0.3$  mm.<sup>39</sup> The present prospective study provides direct comparison of marginal bone level changes at different implant-abutment interfaces that affirms the recent systematic review's conclusion that the marginal bone level changes at CI implant-abutment interfaces are smaller than at other designs.

The primary outcome measure in the present study was peri-implant buccal mucosa position, which is an important determinant of single tooth implant esthetics. Both interproximal (papilla) and midbuccal mucosal zenith positions were found on direct clinical measurement and through measurement of standardized intraoral photographs. This method, recently referred to as gingivomorphometry,<sup>40</sup> permits the careful measurement over time of the position of both the papilla and mucosal zenith by an independent investigator (removed from the clinical procedures) blinded to the treatment group (implant-abutment interface type). For all three implant-abutment interface types, mesial and distal papilla experienced increased measured length (typically  $0.2$  to  $0.3$  mm), and the position of the midbuccal mucosal zenith was unchanged. The clinical and photographic methods both produced similar results (Table 6).

The modestly increased papilla dimension observed among the three groups was as expected. Several investigators have confirmed the observation of Kan et al<sup>12</sup> that interproximal tissue responses are related to the condition of the adjacent teeth and the early observation of Jemt<sup>8</sup> that the papilla adjacent to implants increases in volume over time. The interproximal papilla dimensions may not be directly related to the marginal bone responses evaluated at mesial and distal locations of implants using periapical radiography.

The midbuccal mucosal zenith location relative to the implant crown incisal edge changed little over the 12-month period. This confirms observations of the CI interface system,<sup>18,41</sup> but differs from observations made previously for the FI interface system.<sup>8</sup> Three factors may influence these findings. First, the results represent only 12-month data.<sup>42</sup> Kan et al<sup>43</sup> remarked that for FI implants, the initial (1-year) midbuccal marginal tissue recession of approximately  $0.55$  mm was progressive and exceeded a mean of  $1.13$  mm after 3 years, thus suggesting that this dynamic process may continue beyond 12 months. Midbuccal mucosal zenith positions in conus interfaces were stable over 5-year observation periods.<sup>42,44</sup> Second, most implants was placed in sites grafted using rhBMP-2. The potential influence of this protocol using rhBMP-2 on bone

integrity and evolving mucosal thickness is not known and may have influenced implant survival and peri-implant mucosal parameters. Third, implant positioning may influence outcomes. Although implants were placed by protocol  $3$  mm apical to the planned gingival zenith, the palatal displacement of implant position was not controlled. Buccopalatal implant location or tissue thickness buccal to the implant is a factor controlling tissue stability at dental implants.<sup>45</sup>

The relationships between direct measures of the buccal mucosal zenith position and/or its change over time with esthetic outcomes such as the PES or patient satisfaction remain incompletely defined. They may be clinically important as both the mucosal zenith position and related tooth dimension are significant determinants of recorded patient satisfaction with maxillary anterior tooth appearance.<sup>46</sup> Luo et al<sup>47</sup> reported that the PES was not sufficiently sensitive to assess the change in soft tissue margin. Linear measures as reported here and previously<sup>42,44</sup> may be important tools in outcome measurements.

## CONCLUSIONS

Immediate provisionalization represents one therapeutic approach when using dental implants to replace a single missing anterior tooth. Using a defined surgical protocol, the implants with a CI interface demonstrated significantly less marginal bone loss after 1 year than either the FI or the PS implants. At 1-year follow-up, changes in the buccal mucosal zenith position or papilla dimensions were not discernable among the three different implant designs. Longer term data may reveal possible temporal relationships among implant design, bone responses, and soft tissue esthetic parameters.

## ACKNOWLEDGMENTS

The authors thank Dr. Ann-Sofie Svensson for her coordination of and statistical assistance with this investigation. This study was sponsored by Dentsply Implants (formerly Astra Tech AB). The authors reported no conflicts of interest related to this study.

## REFERENCES

1. Atieh MA, Atieh AH, Payne AG, Duncan WJ. Immediate loading with single implant crowns: A systematic review and meta-analysis. *Int J Prosthodont* 2009;22:378–387.
2. Cannizzaro G, Felice P, Leone M, Checchi V, Esposito M. Flapless versus open flap implant surgery in partially edentulous patients subjected to immediate loading: 1-year results from a split-mouth randomized controlled trial. *Eur J Oral Implantol* 2011;4:177–188.

3. Chen ST, Buser D. Clinical and esthetic outcomes of implants placed in postextraction sites. *Int J Oral Maxillofac Implants* 2009;24 (suppl): 186–217.
4. Cosyn J, Hooghe N, De Bruyn H. A systematic review on the frequency of advanced recession following single immediate implant treatment. *J Clin Periodontol* 2012;39:582–589.
5. den Hartog L, Meijer HJ, Stegenga B, Tymstra N, Vissink A, Raghoobar GM. Single implants with different neck designs in the aesthetic zone: A randomized clinical trial. *Clin Oral Implants Res* 2011;22:1289–1197.
6. Levi A, Psoter WJ, Agar JR, Reisine ST, Taylor TD. Patient self-reported satisfaction with maxillary anterior dental implant treatment. *Int J Oral Maxillofac Implants* 2003;18:113–120.
7. Meijndert L, Meijer HJ, Stellingsma K, Stegenga B, Raghoobar GM. Evaluation of aesthetics of implant-supported single-tooth replacements using different bone augmentation procedures: A prospective randomized clinical study. *Clin Oral Implants Res* 2007;18:715–719.
8. Jemt T. Regeneration of gingival papillae after single-implant treatment. *Int J Periodontics Restorative Dent* 1997;17:326–333.
9. Meijer HJ, Stellingsma K, Meijndert L, Raghoobar GM. A new index for rating aesthetics of implant-supported single crowns and adjacent soft tissues—the Implant Crown Aesthetic Index. *Clin Oral Implants Res* 2005;16:645–649.
10. Fürhauser R, Florescu D, Benesch T, Haas R, Mailath G, Watzek G. Evaluation of soft tissue around single-tooth implant crowns: The pink esthetic score. *Clin Oral Implants Res* 2005;16:639–644.
11. Belsler UC, Grutter L, Vailati F, Bornstein MM, Weber HP, Buser D. Outcome evaluation of early placed maxillary anterior single-tooth implants using objective esthetic criteria: A cross-sectional, retrospective study in 45 patients with a 2- to 4-year follow-up using pink and white esthetic scores. *J Periodontol* 2009;80:140–151.
12. Kan JY, Rungcharassaeng K, Lozada J. Immediate placement and provisionalization of maxillary anterior single implants: 1-year prospective study. *Int J Oral Maxillofac Implants* 2003;18:31–39.
13. Raes F, Cosyn J, Crommelinck E, Coessens P, De Bruyn H. Immediate and conventional single implant treatment in the anterior maxilla: 1-year results of a case series on hard and soft tissue response and aesthetics. *J Clin Periodontol* 2011;38:385–394.
14. Weinländer M, Lekovic V, Spadjic-Gostovic S, Milicic B, Wegscheider WA, Piehslinger E. Soft tissue development around abutments with a circular macro-groove in healed sites of partially edentulous posterior maxilla and mandibles: A clinical pilot study. *Clin Oral Implants Res* 2011;22:743–752.
15. Bressan E, Paniz G, Lops D, Corazza B, Romeo E, Favero G. Influence of abutment material on the gingival color of implant-supported all-ceramic restorations: A prospective multicenter study. *Clin Oral Implants Res* 2011;22:631–637.
16. Hansson S. Implant-abutment interface: Biomechanical study of flat top versus conical. *Clin Implant Dent Relat Res* 2000;2:33–41.
17. Saidin S, Abdul Kadir MR, Sulaiman E, Abu Kasim NH. Effects of different implant-abutment connections on micromotion and stress distribution: Prediction of microgap formation. *J Dent* 2012;40:467–474.
18. Cooper LF, Raes F, Reside GJ, et al. Comparison of radiographic and clinical outcomes following immediate provisionalization of single-tooth dental implants placed in healed alveolar ridges and extraction sockets. *Int J Oral Maxillofac Implants* 2010;25:1222–1232.
19. Esposito M, Grusovin MG, Maghazireh H, Worthington HV. Interventions for replacing missing teeth: Different times for loading dental implants. *Cochrane Database Syst Rev* 2013;28:3.
20. Cooper LF, Ellner S, Moriarty J, et al. Three-year evaluation of single-tooth implants restored 3 weeks after 1-stage surgery. *Int J Oral Maxillofac Implants* 2007;22:791–800.
21. Donati M, La Scala V, Di Raimondo R, Speroni S, Testi M, Berglundh T. Marginal bone preservation in single-tooth replacement: A 5-year prospective clinical multicenter study. *Clin Implant Dent Relat Res* 2013 [Epub ahead of print].
22. Raes F, Cosyn J, De Bruyn H. Clinical, aesthetic, and patient-related outcome of immediately loaded single implants in the anterior maxilla: A prospective study in extraction sockets, healed ridges, and grafted sites. *Clin Implant Dent Relat Res* 2013;15:819–835.
23. Fischer K, Bäckström M, Sennerby L. Immediate and early loading of oxidized tapered implants in the partially edentulous maxilla: A 1-year prospective clinical, radiographic, and resonance frequency analysis study. *Clin Implant Dent Relat Res* 2009;11:69–80.
24. Guarnieri R, Ceccherini A, Grande M. Single-tooth replacement in the anterior maxilla by means of immediate implantation and early loading: Clinical and aesthetic results at 5 years. *Clin Implant Dent Relat Res* 2015;17:314–326.
25. Ostman PO, Wennerberg A, Albrektsson T. Immediate occlusal loading of NanoTite PREVAIL implants: A prospective 1-year clinical and radiographic study. *Clin Implant Dent Relat Res* 2010;12:39–47.
26. Ostman PO, Hupalo M, del Castillo R, et al. Immediate provisionalization of NanoTite implants in support of single-tooth and unilateral restorations: One-year interim report of a prospective, multicenter study. *Clin Implant Dent Relat Res* 2010;12(suppl 1):e47–55.
27. Ostman PO, Wennerberg A, Ekestubbe A, Albrektsson T. Immediate occlusal loading of NanoTite Implants: A prospective 1-year clinical and radiographic study. *Clin Implant Dent Relat Res* 2013;15:809–815.
28. Mura P. Immediate loading of tapered implants placed in postextraction sockets: Retrospective analysis of the 5-year clinical outcome. *Clin Implant Dent Relat Res* 2012;14:565–574.
29. den Hartog L, Slater JJ, Vissink A, Meijer HJ, Raghoobar GM. Treatment outcome of immediate, early and conventional single-tooth implants in the aesthetic zone: A systematic review to survival, bone level, soft-tissue, aesthetics and patient satisfaction. *J Clin Periodontol* 2008;35:1073–1086.
30. Meloni SM, De Riu G, Pisano M, et al. Computer-assisted implant surgery and immediate loading in edentulous ridges with dental fresh extraction sockets. Two years results of a prospective case series study. *Eur Rev Med Pharmacol Sci* 2013;17:2968–2973.
31. Arnhart C, Kielbassa AM, Martinez-de Fuentes R, et al. Comparison of variable-thread tapered implant designs to a standard tapered implant design after immediate loading. A 3-year multicentre randomised controlled trial. *Eur J Oral Implantol* 2012;5:123–136.
32. Lazzara RJ, Porter SS. Platform switching: A new concept in implant dentistry for controlling postrestorative crestal bone levels. *Int J Periodontics Restorative Dent* 2006;26:9–17.
33. Fickl S, Zuhr O, Stein JM, Hürzeler MB. Peri-implant bone level around implants with platform-switched abutments. *Int J Oral Maxillofac Implants* 2010;25:577–581.
34. Enkling N, Jöhren P, Klimberg V, Bayer S, Mericske-Stern R, Jepsen S. Effect of platform switching on peri-implant bone levels: A randomized clinical trial. *Clin Oral Implants Res* 2011;22:1185–1192.
35. Tellemann G, Raghoobar GM, Vissink A, Meijer HJ. Impact of platform switching on inter-proximal bone levels around short implants in the posterior region; 1-year results from a randomized clinical trial. *J Clin Periodontol* 2012;39:688–697.
36. Enkling N, Jöhren P, Katsoulis J, et al. Influence of platform switching on bone-level alterations: A three-year randomized clinical trial. *J Dent Res* 2013 [Epub ahead of print].
37. Al-Nsour MM, Chan HL, Wang HL. Effect of the platform-switching technique on preservation of peri-implant marginal bone: A systematic review. *Int J Oral Maxillofac Implants* 2012;27:138–145.
38. De Bruyn H, Raes F, Cooper LF, et al. Three-years clinical outcome of immediate provisionalization of single Osseospeed implants in extraction sockets and healed ridges. *Clin Oral Implants Res* 2013;24:217–223.
39. Laurell L, Lundgren D. Marginal bone level changes at dental implants after 5 years in function: A meta-analysis. *Clin Implant Dent Relat Res* 2011;13:19–28.
40. Weinländer M, Lekovic V, Spadjic-Gostovic S, Milicic B, Krennmaier G, Plenck H Jr. Gingivomorphometry - esthetic evaluation of the crown-mucogingival complex: A new method for collection and measurement of standardized and reproducible data in oral photography. *Clin Oral Implants Res* 2009;20:526–530.
41. Sanz M, Cecchinato D, Ferrus J, et al. Implants placed in fresh extraction sockets in the maxilla: Clinical and radiographic outcomes from a 3-year follow-up examination. *Clin Oral Implants Res* 2013;25:321–327.
42. Buser D, Chappuis V, Kuchler U, et al. Long-term stability of early implant placement with contour augmentation. *J Dent Res* 2013;92 (suppl):1765–825.
43. Kan JY, Rungcharassaeng K, Lozada JL, Zimmerman G. Facial gingival tissue stability following immediate placement and provisionalization of maxillary anterior single implants: A 2- to 8-year follow-up. *Int J Oral Maxillofac Implants* 2011;26:179–187.
44. Cooper LF, Reside GJ, Raes F, et al. Provisionalization of dental implants placed in healed alveolar ridges and extraction sockets. A 5 year prospective evaluation. *Int J Oral Maxillofac Implants* 2014;29:709–717.
45. Evans CD, Chen ST. Esthetic outcomes of immediate implant placements. *Clin Oral Implants Res* 2008;19:73–80.
46. Zagar M, Knezović Zlatarić D. Influence of esthetic dental and facial measurements on the Caucasian patients' satisfaction. *J Esthet Restor Dent* 2011;23:12–20.
47. Luo Z, Zeng R, Luo Z, Chen Z. Single implants in the esthetic zone: Analysis of recent peri-implant soft tissue alterations and patient satisfaction. A photographic study. *Int J Oral Maxillofac Implants* 2011;26:578–586.